IBEROAMERICAN JOURNAL OF MEDICINE
iberoamericanjm
Journal homepage: www.iberoamjmed.com

Case Report

Class IC Atrial Flutter Presenting as a Wide Complex Tachycardia: Lessons from a Case Report

Miguel Aurrecoechea-Perea [a,*], *Hebert David Ayala-More* [b], *Isaac Vidal-Valdivia* [a], *Teresa Gonzalo-Moreno* [a], *María Gota-Nieto* [a]

[a] *Department of Cardiology, San Pedro University Hospital, Logroño, Spain*
[b] *Mater Department of Cardiology, Arrhythmia Unit, San Pedro University Hospital, Logroño, Spain*

ARTICLE INFO

Article history:
Received 21 October 2025
Received in revised form 08 March 2026
Accepted 24 March 2026

Keywords:
Wide QRS complex tachycadia
Flecainide
Atrial flutter
Atrial fibrillation
Antiarrhytmic
Use dependence

ABSTRACT

Flecainide is an established antiarrhythmic agent for atrial fibrillation (AF), but monotherapy without atrioventricular nodal blockade can precipitate atrial flutter (AFL) with 1:1 conduction. This may result in a wide QRS complex tachycardia due to use-dependent conduction delay, mimicking ventricular tachycardia (VT).

We present a case of a wide QRS complex tachycardia in a patient with paroxysmal AF on oral flecainide monotherapy, initially interpreted as VT and managed with intravenous amiodarone. Class IC antiarrhythmic agents may cause progressive QRS widening because of the use-dependence phenomenon. This case underscores the importance of integrating clinical context with ECG analysis and acute and long-term management approaches in symptomatic paroxysmal atrial fibrillation.

© 2026 The Authors. Published by Iberoamerican Journal of Medicine. This is an open access article under the CC BY license (http://creativecommons. org/licenses/by/4.0/).

* *Corresponding author.*
E-mail address: miaurreco@gmail.com
ISSN: 2695-5075 / © 2026 The Authors. Published by Iberoamerican Journal of Medicine. This is an open access article under the CC BY license (http://creativecommons. org/licenses/by/4.0/).
https://doi.org/10.53986/ibjm.2026.0009

Aleteo auricular de clase IC que se presenta como una taquicardia de complejo ancho: lecciones de un caso clínico

INFO. ARTÍCULO

Historia del artículo:
Recibido 21 Octubre 2025
Recibido en forma revisada 058 Marzo 2026
Aceptado 24 Marzo 2026

Palabras clave:
Taquicardia con complejo QRS ancho
Flecainida
Aleteo auricular
Fibrilación auricular
Antiarrítmico
Dependencia de uso

RESUMEN

La flecainida es un antiarrítmico de uso establecido para la fibrilación auricular (FA), pero la monoterapia sin bloqueo del nódulo auriculoventricular puede precipitar un aleteo auricular (AA) con conducción 1:1. Esto puede resultar en una taquicardia con complejo QRS ancho debido a un retraso de la conducción dependiente del uso, simulando una taquicardia ventricular (TV).

Presentamos un caso de taquicardia con complejo QRS ancho en un paciente con FA paroxística en monoterapia con flecainida oral, inicialmente interpretada como TV y tratada con amiodarona intravenosa. Los antiarrítmicos de clase IC pueden causar un ensanchamiento progresivo del QRS debido al fenómeno de dependencia del uso. Este caso subraya la importancia de integrar el contexto clínico con el análisis del ECG y los enfoques de manejo agudo y a largo plazo en la fibrilación auricular paroxística sintomática.

© 2026 Los Autores. Publicado por Iberoamerican Journal of Medicine. Éste es un artículo en acceso abierto bajo licencia CC BY (http://creativecommons. org/licenses/by/4.0/).

HOW TO CITE THIS ARTICLE: Aurrecoechea-Perea M, Ayala-Moree HD, Vidal-Valdivia I, Gonzalo-Moreno T, Gota-Nieto M. Class IC Atrial Flutter Presenting as a Wide Complex Tachycardia: Lessons from a Case Report. Iberoam J Med. 2026;8(2):66-70. doi: 10.53986/ibjm.2026.0009.

1. INTRODUCTION

Wide QRS complex tachycardias are a diagnostic challenge in clinical practice. The differential diagnosis includes ventricular tachycardia (VT) and supraventricular tachycardia (SVT) conducted with aberrancy (either due to functional or pre-existing bundle branch block) or via an accessory atrioventricular pathway. VT accounts for most cases and is associated with considerable risk to life [1].

A detailed electrocardiographic evaluation facilitates the differential diagnosis. Findings such as atrioventricular (AV) dissociation capture beats and fusion beats are considered highly suggestive of a ventricular origin. Additionally, diagnostic algorithms like the Brugada algorithm (based on precordial lead concordance, RS intervals > 100 ms, and morphologic criteria in V1–V6) and the Vereckei algorithm (focused on lead aVR) have been validated with high sensitivity and specificity in selected cohorts. However, there remain wide QRS tachycardias in which a definitive diagnosis cannot be established, particularly in patients under antiarrhythmic therapy, where the accuracy of the algorithms is reduced [1-3].

Antiarrhythmic drugs commonly used to maintain sinus rhythm include those from class IC (e.g., flecainide) and class III (e.g., amiodarone) of the Vaughan–Williams classification. These agents can cause wide QRS tachycardias, either by prolongation of the QT interval (class III) or via the “use-dependent” phenomenon (class IC) [4].

It is also essential to integrate the clinical context. A prior history of myocardial infarction, congestive heart failure, or recent angina markedly increases the positive predictive value for VT [1].

We report the case of a patient receiving chronic flecainide therapy who developed a wide QRS tachycardia due to a use-dependent phenomenon, which was initially managed as VT. We discuss the importance of a detailed ECG analysis and patient’s clinical context, together with therapeutic considerations extending beyond the acute phase.

2. CASE REPORT

A 62-year-old man with hypertension and a history of cavotricuspid isthmus (CTI) ablation for recurrent episodes of atrial flutter (AFL) in 2015. Since the procedure, he has been experiencing 2–3 symptomatic episodes of paroxysmal atrial fibrillation (AF) per year. At his most recent evaluation, laboratory findings were unremarkable and echocardiography showed preserved left ventricular ejection fraction without evidence of structural heart disease. His long-term medications included apixaban, lisinopril and flecainide.

In May 2025, he presented to the emergency department with an episode of palpitations longer on duration than usual. As symptoms persisted, an extra dose of flecainide was taken, without success.

At presentation, the patient was hemodynamically stable,

with a blood pressure of 110/77 mmHg and a heart rate of 179 beats per minute (bpm). An electrocardiogram (Figure 1) was obtained, with an initial impression of VT. An intravenous bolus of amiodarone was administered, followed by continuous infusion. Emergency laboratory testing revealed no significant abnormalities. An adequate reduction in ventricular rate was achieved, slowing the rhythm and unmasking an AFL with narrow QRS and 2:1 AV conduction at 100 bpm (Figure 2). The patient ultimately reverted to sinus rhythm.

Figure 1: *Atrial flutter with 1:1 conduction in a patient on oral flecainide (pill-in-the pocket strategy). Wide QRS complexes mimicking ventricular tachycardia.*

The cardiology service was consulted. After a detailed evaluation of the ECG tracings and consideration of the clinical context, the leading diagnostic suspicion was Class IC–induced AFL conducted with aberrancy. The patient was admitted to the cardiology ward for monitoring, treatment adjustment, and consideration of an electrophysiological study.

Transthoracic echocardiography demonstrated normal left ventricular systolic function and a severely dilated left atrium (indexed volume of 56 mL/m²). An electrophysiology study was performed, which successfully induced typical counterclockwise AFL. CTI re-ablation was carried out, restoring bidirectional isthmus block.

Patient was discharged on amiodarone for rhythm control, apixaban for stroke prevention and his antihypertensive therapy was optimized. Follow up with an electrophysiologist for evaluation of catheter ablation was scheduled.

3. DISCUSSION

Class IC antiarrhythmic drugs such as flecainide exhibit use-dependence depressant effects on fast sodium channels, reducing maximal upstroke velocity (phase 0 slope) of the cardiac action potential [5]. They have a high affinity for sodium channels in the open state. As heart rate increases, the degree of sodium channel inhibition also rises, leading to greater conduction slowing during tachycardia. On the surface ECG, this is reflected as QRS interval prolongation. Moreover, flecainide can convert AF into AFL with slowed conduction, facilitating 1:1 atrioventricular conduction at very high rates if the AV node is not protected. The resulting wide QRS complexes can mimic VT, potentially leading to inappropriate management of the tachyarrhythmia [4, 6].

To mitigate this risk, current AF guidelines recommend concomitant use of AV nodal–blocking drugs such as beta-blockers, verapamil, or diltiazem [7].

Initial ECG showed a wide QRS regular tachycardia at 190 bpm, mimicking VT. If uncertainty is present, the safest approach is to manage it as VT [1]. In our patient, an amiodarone bolus followed by a continuous infusion was administered. The ventricular rate slowed and AFL with narrow QRS and 2:1 AV conduction emerged.

The clinical context of absent structural heart disease, flecainide use, and hemodynamic stability supported the

consideration of AFL with 1:1 conduction and ventricular aberrancy as an alternative diagnosis to VT. Given the patient's stable condition, it might have been useful to employ AV nodal blocking drugs such as metoprolol or a calcium-channel blocker like diltiazem. In this setting, amiodarone may enhance sodium channel blockade (through a use-dependence effect independent of criteria with contextual clinical analysis. When in doubt, the safest strategy remains to treat the rhythm as VT until conclusive evidence is obtained.

Class IC antiarrhythmic agents should be co-administered with AV nodal blocking agents, such as beta-blockers or calcium channel blockers.

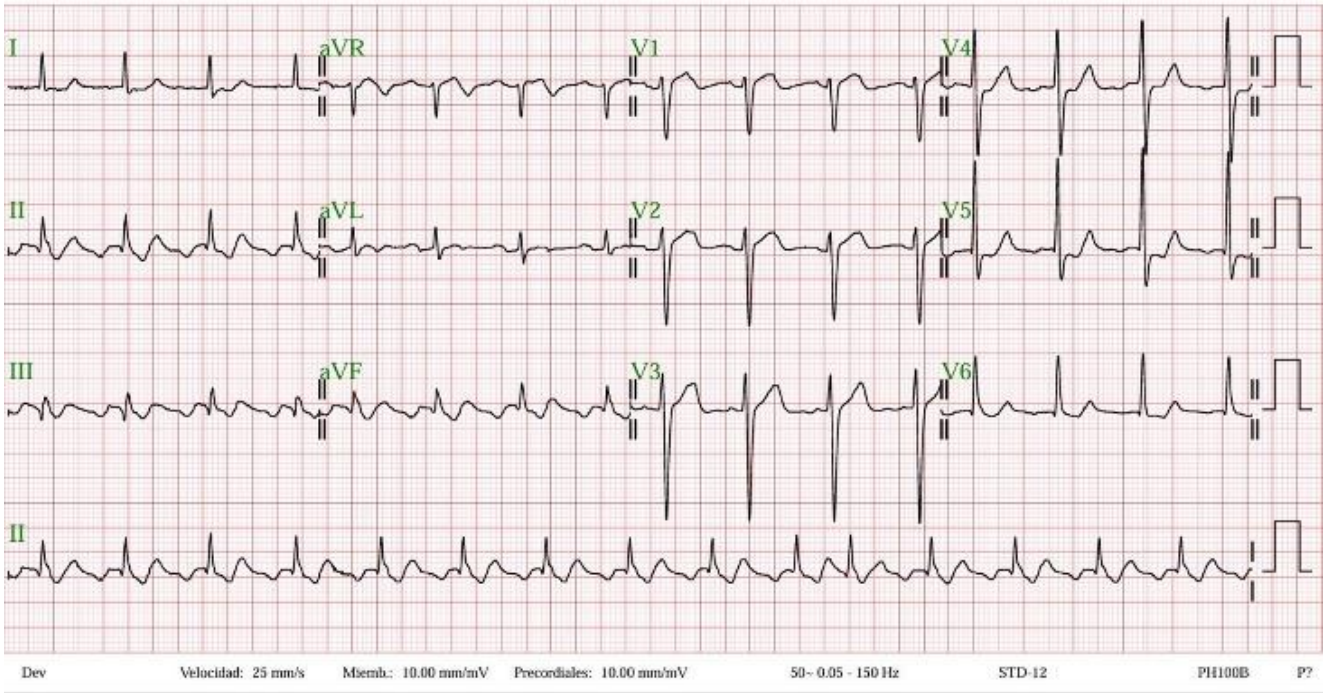

Figure 2: *Atrial flutter with 2:1 atrioventricular conduction at 100 beats per minute.*

flecainide), resulting in further QRS widening and potential clinical deterioration [1].

After the acute phase, diagnostic re-evaluation identified the true nature of the arrhythmia and allowed planning of a definitive approach with CTI re-ablation.

For long-term rhythm control, antiarrhythmic drugs remain a fundamental pillar in symptomatic paroxysmal AF, though their utility is limited by moderate efficacy and possible systemic side effects [8]. In the latest clinical practice guidelines, catheter ablation (typically via pulmonary vein isolation) has been established as a highly effective option to reduce AF burden and improve quality of life in symptomatic patients. It is now recommended as a first-line strategy for rhythm control in this population (Class I, Level of Evidence A) [7].

4. COCNLUSIONS

In summary, a wide QRS tachycardia requires an integrated diagnostic approach that combines electrocardiographic

5. CONFLICT OF INTERESTS

The authors have no conflict of interest to declare. The authors declared that this study has received no financial support.

6. REFERENCES

1. Alzand BS, Crijns HJ. Diagnostic criteria of broad QRS complex tachycardia: decades of evolution. Europace. 2011;13(4):465-72. doi: 10.1093/europace/euq430.

2. Katritsis DG, Brugada J. Differential Diagnosis of Wide QRS Tachycardias. Arrhythm Electrophysiol Rev. 2020;9(3):155-60. doi: 10.15420/aer.2020.20.

3. Vereckei A. Current algorithms for the diagnosis of wide QRS complex tachycardias. Curr Cardiol Rev. 2014;10(3):262-76. doi: 10.2174/1573403x10666140514103309.

4. Andrikopoulos GK, Pastromas S, Tzeis S. Flecainide: Current status and perspectives in arrhythmia management. World J Cardiol. 2015;7(2):76-85. doi: 10.4330/wjc.v7.i2.76.

5. Basza M, Maciejewski C, Bojanowicz W, Balsam P, Grabowski M, Mitkowski P, et al. Flecainide in clinical practice. Cardiol J. 2023;30(3):473-482. doi: 10.5603/CJ.a2023.0018.

6. Crijns HJ, van Gelder IC, Lie KI. Supraventricular tachycardia mimicking ventricular tachycardia during flecainide treatment. Am J Cardiol. 1988;62(17):1303-6. doi: 10.1016/0002-9149(88)90282-2.

7. Van Gelder IC, Rienstra M, Bunting KV, Casado-Arroyo R, Caso V, Crijns HJGM, et al. 2024 ESC Guidelines for the management of atrial fibrillation developed in collaboration with the European Association for Cardio-Thoracic Surgery (EACTS). Eur Heart J. 2024;45(36):3314-414. doi: 10.1093/eurheartj/ehae176.

8. Heijman J, Voigt N, Dobrev D. New directions in antiarrhythmic drug therapy for atrial fibrillation. Future Cardiol. 2013;9(1):71-88. doi: 10.2217/fca.12.78.